

Bone Suppression for Chest Radiographic Images

Introduction

Chest radiography remains the most commonly used method for screening and diagnosing lung diseases, such as lung cancer, pneumothorax, interstitial disease, emphysema and many others. The detectability of a lung disease on a chest radiograph is affected by the signal-to-noise ratio (SNR) in the image. High-contrast bone structures are major noise contributors that significantly reduce the SNR in chest radiographic images. A signal of interest in a chest radiograph could be either partially or completely obscured, or “overshadowed,” by the highly contrasted bone structures surrounding it. This is why removing the bone structures, especially the posterior rib and clavicle structures, is highly desirable to increase the visibility of soft tissue.

Advanced X-ray imaging techniques, such as 3D imaging (CT and tomosynthesis) and dual-energy subtraction, have been developed to remove the overlapping bone-structure noise to improve the visibility of soft tissue. However, these advanced imaging technologies cannot replace the role of chest radiography for its efficiency, low radiation dose, low cost, and most particularly, its portability and mobility. Chest radiography plays an essential role for patients in intensive care units (ICUs). Advanced imaging techniques have not been optimized for the use in ICUs where device portability and mobility are required or highly desired.

Carestream’s Bone Suppression Software offers a solution to suppress bone structures, including posterior ribs and clavicles, in conventional and portable chest X-ray images. The solution requires no additional procedure or radiation dose. The software processes the chest radiographic images using machine-learning and pattern-recognition technologies to accurately detect the rib and clavicle structures and estimate the structure profiles used in the subsequent suppression step. This bone-suppression process is limited to the detected structures to keep unnecessary changes to the original images at minimal levels. The software is designed to suppress the high-contrast bone structures while maintaining the integrity of image quality, in particular the contrast-detail level, as closely as possible to that of the original images.

CARESTREAM Bone Suppression Software

The CARESTREAM Bone Suppression Software takes in an input image from a DR capture device and processes the image in the steps as shown in Figure 1. The image processing includes five major steps: 1) lung segmentation, 2) rib and clavicle structure detection, 3) rib and clavicle edge detection, 4) rib and clavicle profile estimation, and 5) suppression based on the estimated profiles. The bone-suppression software outputs an image that suppresses both the posterior rib and clavicle structures. The suppressed image is then enhanced the same way as the original image for visualization, and used as a companion view.

Image examples shown in Figure 2 illustrate some of the steps for rib suppression. The rib detection is performed within the segmented lung field. The detected ribs in Figure 2(c) are further processed to accurately detect the rib edges. Rib profiles are estimated for the detected ribs and used in the subsequent suppression process. The suppression process is limited to the rib areas only; areas outside of the ribs are not affected. In addition, the rib edges are sufficiently suppressed as shown in Figure 2(d). No additional image processing, in particular, any smoothing operation, is performed to reduce the image sharpness. It’s critical to maintain the image quality (i.e., the contrast-detail level) of bone-suppressed images as closely as possible to that of the original images so that both larger, low-contrast abnormalities (as shown in Figure 4) and subtle line structures (a pneumothorax, as shown in Figure 3) can benefit from the suppression of bone structure noise with improved detectability.

In the image-enhancement step, the standard CARESTREAM EVP Plus Software (on both the DirectView and ImageView platforms) is used to produce the rib-suppressed companion view. The rib-suppressed images, however, can be further enhanced by other Carestream image-processing software, e.g., pneumothorax visualization enhancement (CARESTREAM Pneumothorax Visualization Software), as shown in the example in Figure 3(c). Currently, this option is not offered.

White Paper | CARESTREAM Bone Suppression Software

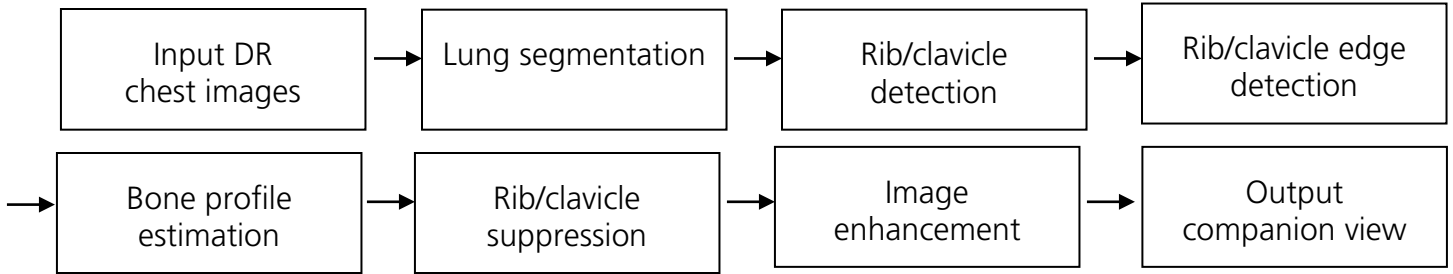


Figure 1: Image-processing chain to generate a bone-suppressed companion view

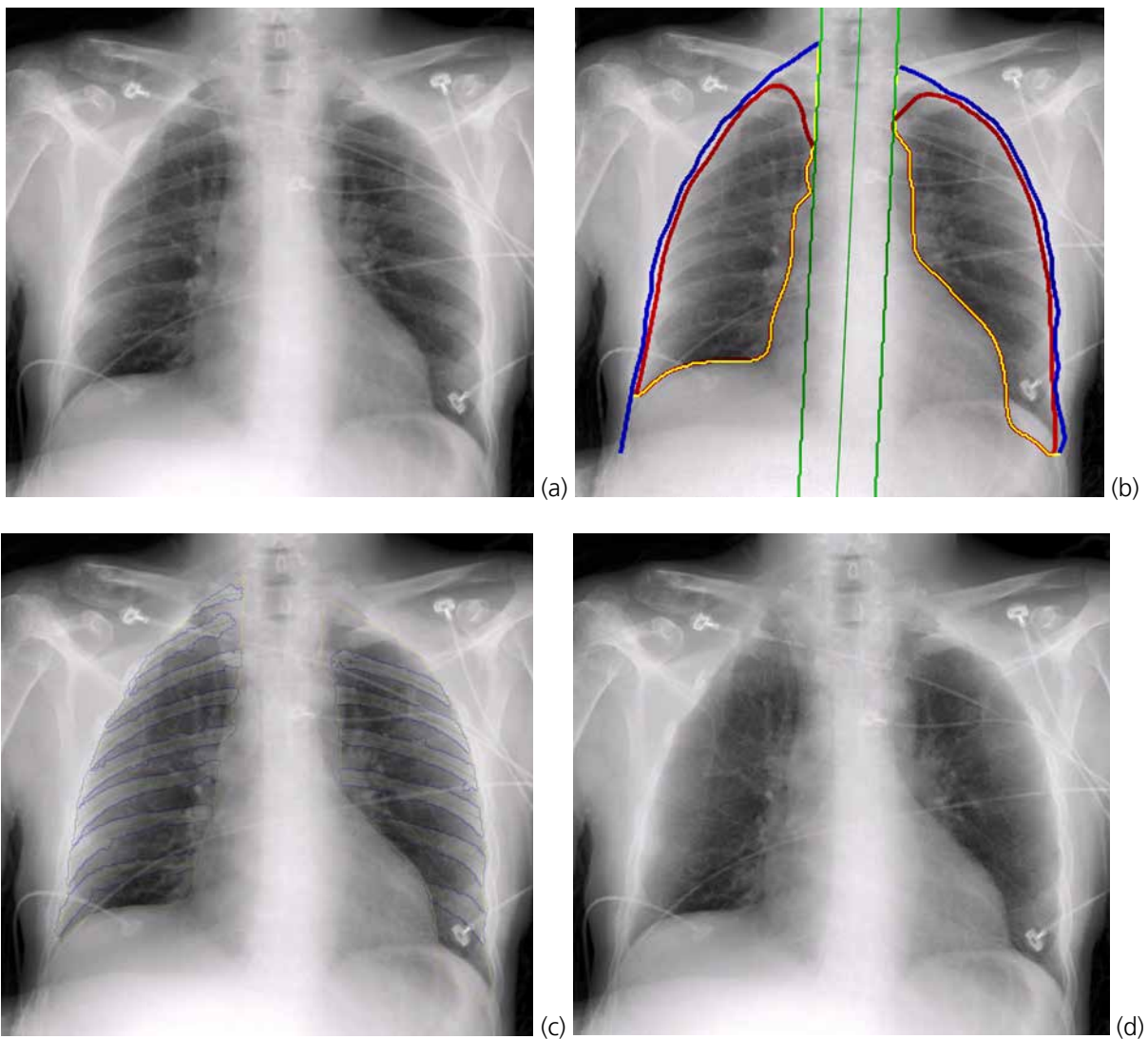


Figure 2: a) An input portable chest radiographic image; b) the image with segmented lung field; c) the image with detected ribs; and d) the image with ribs suppressed.

White Paper | CARESTREAM Bone Suppression Software

Figure 3 shows a portable chest image with a pneumothorax in the upper right lung and its rib-suppressed companion view. The rib-suppressed image is further processed using the CARESTREAM Pneumothorax Visualization Software. A region containing the pneumothorax is selected from each of the three images. As Figure 3(d) shows, the contrast detail is well-preserved in the rib-suppressed images for visualizing the signs of the subtle pneumothorax, i.e., the edge of the collapsed lung and the difference in the texture between the regions separated by the edge.

Figure 4 shows a chest image with a large abnormality, confirmed by CT images, behind the right clavicle and the top rib. As shown in Figure 4(b), the shape and size of the abnormality are much easier to see after suppression of the clavicle and rib. This demonstrates that the software estimates the bone-structure profiles accurately and doesn't over-suppress areas where a large structure or abnormality presents.

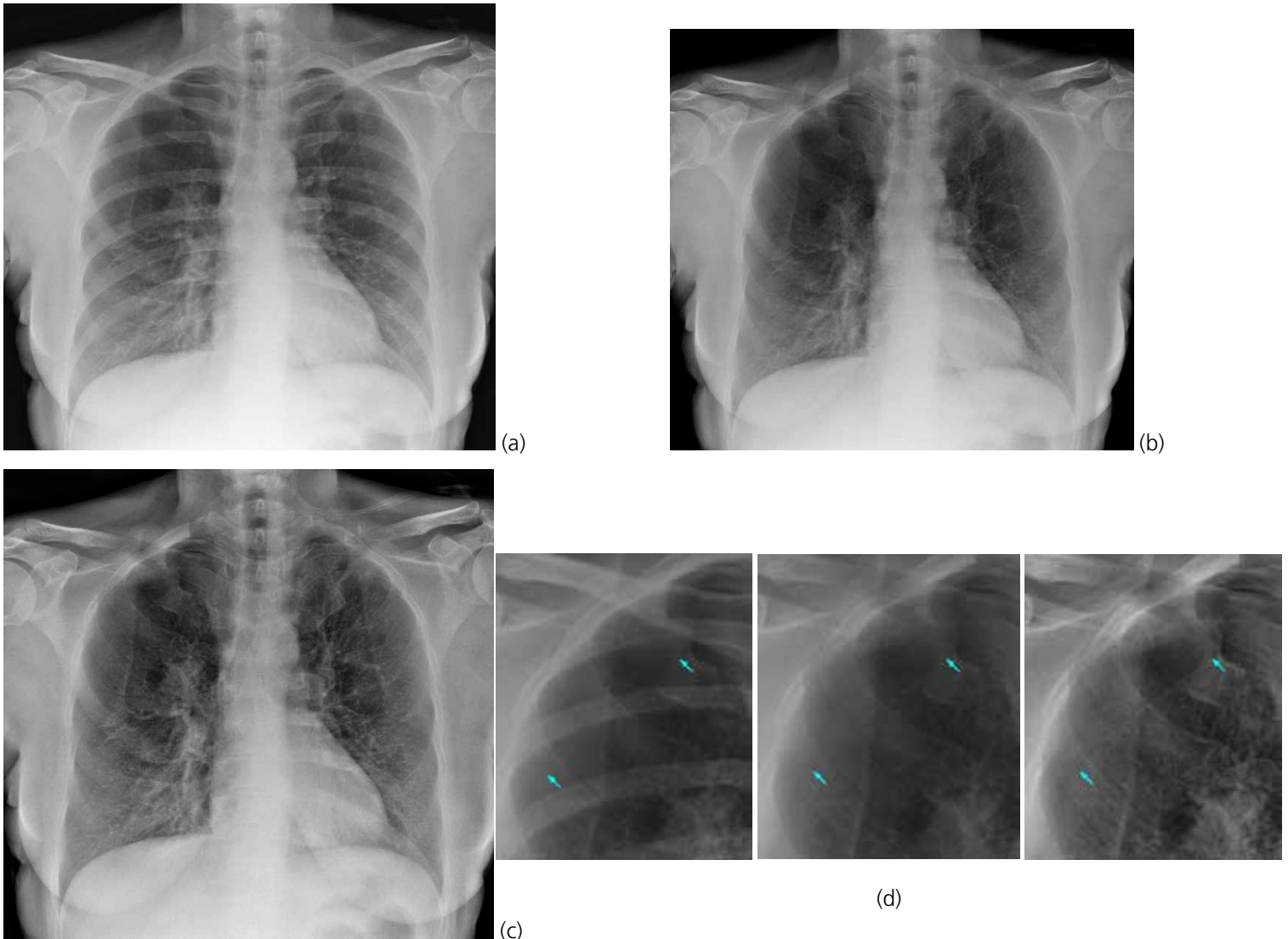
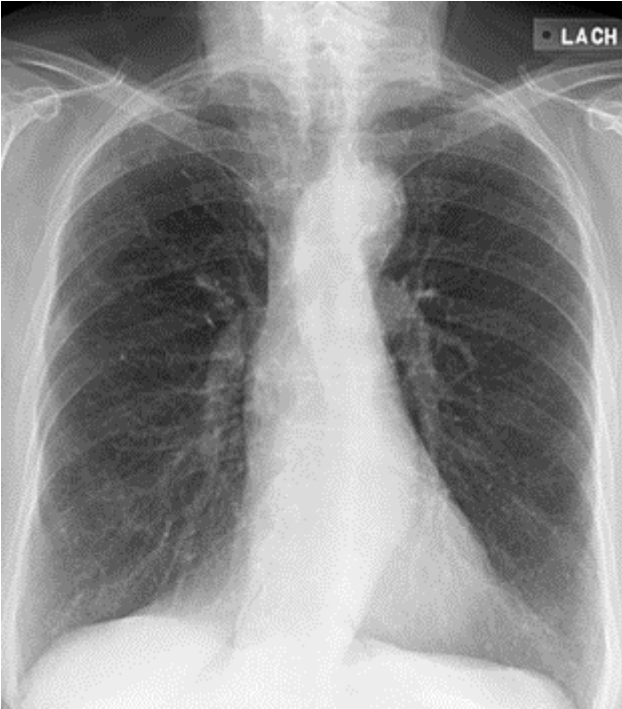
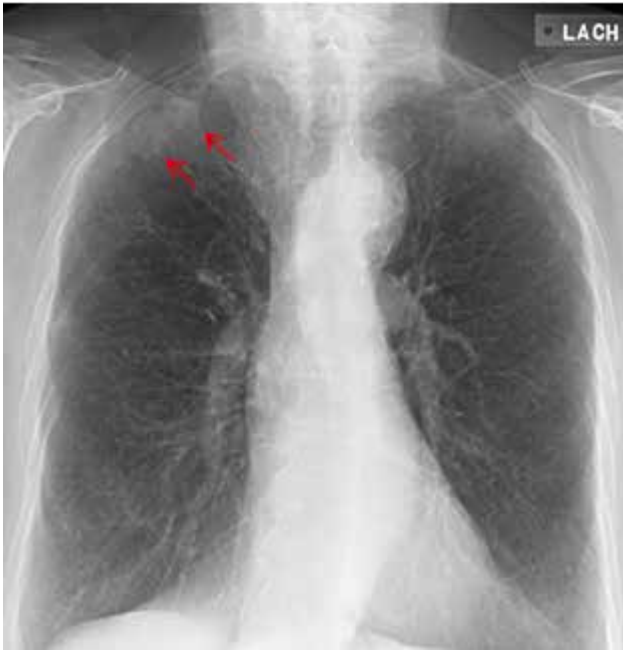


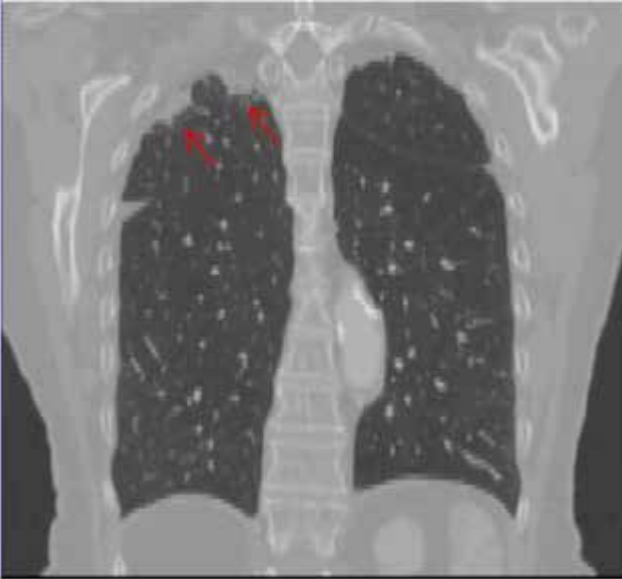
Figure 3: A portable chest image before (a) and after bone suppression (b). An enhanced image (c) generated using the CARESTREAM Pneumothorax Visualization Software. Regions of interest (d) feature a pneumothorax from the upper right lung, demonstrating that the contrast detail is well-preserved after rib suppression.



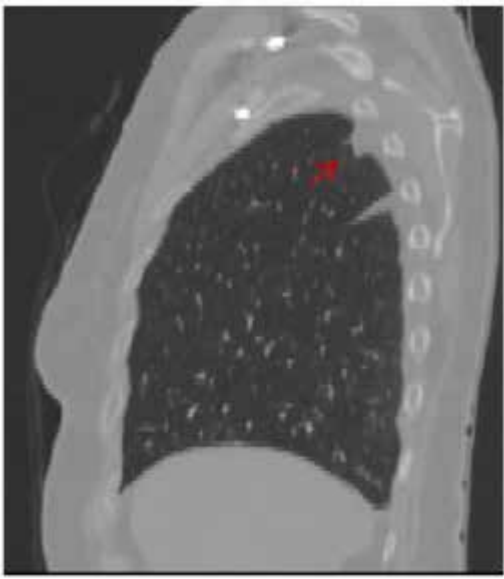
(a)



(b)



(c)



(d)

Figure 4: A conventional chest image (a) and its rib-suppressed companion view (b). CT images (coronal and sagittal views) from the same patient. Arrows indicate the same large abnormalities.

Bone Suppression Companion View Improves the Detection of Lung nodules and Pneumothoraces

To demonstrate the benefit of CARESTREAM Bone Suppression Software, reader studies were performed to evaluate reader performance in detecting lung nodules and pneumothoraces with and without a bone suppression companion view. Five Board Certified radiologists with various levels of experience in chest radiographic images participated in both studies. Readers were asked to mark the locations of lung diseases including nodule, pneumothorax, fibrosis, granuloma, interstitial, pleural diseases and other types of abnormalities on a chest radiograph first without the companion view. They were then asked to make any change to their initial detections after the companion view was presented. Readers were allowed to mark additional detections, change their initial detections from one type of lung diseases to another or remove their initial detections. In addition, they were asked to provide a subjective rating (significantly better, better, the same or worse) on how well they can perceive or characterize the lung parenchyma and abnormalities and their confidences (more, the same or less) on their diagnoses regarding the presence or absence of an abnormality on each case after the companion view was presented.

Nodule Detection Study

Conventional digital PA chest radiographs from 50 subjects were used in the nodule detection study. These images were selected from a publicly available database, the Lung Image Database Consortium (LIDC) and image database resource initiative (IDRI), which was collected to establish a common lung nodule database for both CT chest scans and digital chest radiographs¹. Possible nodules of size between 3mm and 30mm (measured on CT) were first identified on the CT scans. The locations of these CT-confirmed nodules were marked on chest radiographs by four experienced thoracic radiologists with annotated confidences (“definitely not visible”, “questionably visible” or “definitely visible”). Details on the nodule truth establishment can be found elsewhere¹. A total of 49 CT-confirmed nodules were identified as either “questionably visible” or “definitely visible” on the 50 DR images.

Results from the nodule detection study showed that the average sensitivity increased from 51% to 58.2% after the rib-suppressed companion view was presented. Overall, the five readers have an average of 7.2% increase in sensitivity to detect CT-confirmed nodules at a statistically significant level

($p=0.01$). The average number of false-positive (FP) detections per image increased from the initial 0.244 to 0.28 per image. The difference was not at a statistically significant level ($p=0.25$).

Pneumothorax Detection Study

Portable CR chest radiographic images from 65 subjects were used in the pneumothorax detection study. Thirty-seven were confirmed with at least one pneumothorax. These images were selected from a database consisting of over 200 portable CR images, which were collected to evaluate CARESTREAM Pneumothorax Visualization Software². Images were selected to represent the mix of pneumothoraces with different subtleties based on the size and subtlety rated by two thoracic radiologists.

Pneumothorax detection results showed that the average sensitivity of five readers increased from 74% to 83.2% after the rib-suppressed companion view was presented. Analysis based on the Student t test for paired data showed that the average improvement (9.2%) was statistically significant ($p=0.001$). Overall, each of the five readers gained at least 8.1% improvement in sensitivity. This improvement led the top three performers to achieve a sensitivity of 89%, 97% and 100%, respectively, in detecting pneumothoraces with no additional FP detection. The average number of FP detections per image for the five readers increased from the initial 0.025 to 0.040 per image. The difference, however, was not at a statistically significant level ($p=0.19$). We showed that the enhancement of the rib-suppressed image using the CARESTREAM Pneumothorax Visualization Software can further improve the pneumothorax detection rate by an additional 8% for the two lower performers.

Impact on the Confidence

Analysis of the subjective ratings from the two studies showed the use of the rib-suppressed companion view improved readers' ability to characterize the lung parenchyma and the abnormalities. On average, they ranked their ability to characterize the parenchyma and abnormalities as significantly better or better on 74% and 59%, respectively, of all the images (115) after the rib-suppressed companion view was presented. This was reflected on their improved confidence in making diagnoses regarding the presence or absence of an abnormality. Based on their ratings, they were more confident to make diagnoses on 58% of the images after the companion view was presented.

White Paper | CARESTREAM Bone Suppression Software

Summary

Study results showed that the use of CARESTREAM Bone Suppression Software improved radiologists' ability to characterize the lung parenchyma and abnormalities and their confidences in making diagnoses regarding the presence or absence of an abnormality on chest radiographs. The nodule detection study showed that the use of bone suppression significantly improved radiologists' ability to detect CT-confirmed nodules by 7.2% in sensitivity with an increase FP detection rate of 0.04/image. The pneumothorax detection study showed that the use of bone suppression improved individual radiologist's ability to detect pneumothoraces by at least 8.1% in sensitivity with no or a slightly increased FP detection rate (0.015/image).

The interpretation of chest radiographs is very challenging. The appearances or characteristics of various lung diseases can vary dramatically in terms of their size, shape and contrast. It is critical that a bone suppression solution is capable of preserving the image details so that the SNR can be improved for a range of lung diseases after bone suppression. The findings in the reader studies demonstrated the capability of CARESTREAM Bone Suppression Software to improve the detection of lung diseases of different characteristics, e.g., lung nodules and pneumothoraces. We expect the software to provide radiologists and clinicians in ICUs a means to enhance their overall experiences in chest radiograph interpretation with improved effectiveness and efficiency.

References:

- ¹ Armato SG III, McLennan G, Bidaut L, McNitt-Gray MF, Meyer CR, Reeves AP, Zhao B, Aberle DR, Henschke CI, Hoffman EA, Kazerooni EA, MacMahon H, van Beek EJR, Yankelevitz D, et al.: The Lung Image Database Consortium (LIDC) and Image Database Resource Initiative (IDRI): A completed reference database of lung nodules on CT scans. *Medical Physics*, 38: 915--931, 2011.
- ² Shoushtari H, Ley-Zaporozhan J, Karimzad Y, Menezes R, Odedra D, Jimenez-Juan L, Leon Zelovitsky L, Paul NS: Enhanced Pneumothorax Visualization in ICU Patients, Annual Meeting of Radiological Society of North American (RSNA), December 2013.